

Entodermoscopy: A New Tool for Diagnosing Skin Infections and Infestations

Iris Zalaudek^a Jason Giacomel^b Horacio Cabo^c Alessandro Di Stefani^d
Gerardo Ferrara^e Rainer Hofmann-Wellenhof^a Joseph Malvehy^g Susana Puig^g
Wilhelm Stolz^h Giuseppe Argenziano^f

^aDepartment of Dermatology, Medical University of Graz, Graz, Austria; ^bMends St Medical Centre, South Perth, Australia; ^cInstituto de Investigaciones Médicas, A. Lanari University of Buenos Aires, Buenos Aires, Argentina; ^dDepartment of Dermatology, University Tor Vergata, Rome, ^ePathologic Anatomy Service, Gaetano Rummo General Hospital, Benevento, and ^fDepartment of Dermatology, Second University of Naples, Naples, Italy; ^gMelanoma Unit, Department of Dermatology, Hospital Clinic, IDIBAPS, Barcelona, Spain; ^hClinic of Dermatology and Allergology, Hospital München Schwabing, München, Germany

Key Words

Dermoscopy · Human parasites · Skin infection · Skin infestation

Abstract

Background: There is upcoming evidence that dermoscopy facilitates the in vivo diagnosis of skin infections and infestations. As such, dermoscopy connects the research fields of dermatologists and entomologists, opening a new research field of 'entodermoscopy'. **Objective:** To provide an overview on the current applications of entodermoscopy. **Methods:** Systematic review of the English- and German-language literature by searches of Medline, Medscape and abstracts of the 1st World Congress of the International Dermoscopy Society. **Results:** Dermoscopic patterns have been described for viral warts, molluscum contagiosum, scabies, pediculosis, tinea nigra, tungiasis, cutaneous larva migrans, ticks and reactions to spider leg spines. Besides the diagnostic role of dermoscopy, there is increasing evidence that it

can also assist in the monitoring of treatment efficacy for some of these conditions. **Conclusion:** Although most of the current available literature is based on single observations and small case studies rather than controlled trials, an increasing interest in this field can be observed.

Copyright © 2008 S. Karger AG, Basel

Introduction

Viral warts, mollusca contagiosa, scabies and pediculosis are ubiquitous skin infections or infestations affecting worldwide millions of humans per year. Others, such as tungiasis, cutaneous larva migrans (CLM), tinea nigra or ticks are limited to certain geographic areas [1]. However, due to the frequency of worldwide travel, it might be expected that individuals presenting with these conditions outside the usual geographic area will be increasingly seen in clinical practice.

KARGER

Fax +41 61 306 12 34
E-Mail karger@karger.ch
www.karger.com

© 2008 S. Karger AG, Basel
1018–8665/08/2161–0014\$24.50/0

Accessible online at:
www.karger.com/drm

Iris Zalaudek, MD
Department of Dermatology, Medical University of Graz
Auenbruggerplatz 8
AT-8036 Graz (Austria)
Tel. +43 676 332 8269, Fax +43 316 385 2466, E-Mail iris.zalaudek@meduni-graz.at

Delayed and incorrect diagnosis of infectious diseases has a considerable impact on the health care system, causing significant spread of disease with its consequence of rising morbidity and drug resistance, respectively. The diagnosis of skin infections is usually based on specific clinical features, sometimes combined with microscopic or other laboratory investigations [1–3].

This said, it must be admitted that the latter investigations are not always available in private practice. Because referring patients to specialized centers for microscopic or laboratory examinations may not only be time-consuming (due to hospital waiting lists), but also incur high costs, the so-called 'ex adjuvantibus' treatment, based solely on the clinical suspicion of a skin infection, is unfortunately a common practice. The latter factor, along with the over-the-counter use of antimicrobial medications is thought to be, at least partially, responsible for an increasingly observed drug resistance of human parasites, promoting the vicious cycle of spread and resistance of human skin infections [2].

Dermoscopy is a noninvasive technique that gained popularity for the diagnosis of pigmented and nonpigmented skin tumors because it improves the diagnostic accuracy compared to the naked eye examination [4]. The dermatoscope, a modified magnifying lens, renders the skin surface translucent and allows the visualization of submacroscopic structures located in the epidermis and upper dermis [5]. For this reason, dermoscopy is generally regarded as a link between the clinical (macroscopic) and histopathologic (microscopic) examination. New generations of commercially available hand-held dermatoscopes operate at 10-fold magnification, are relatively inexpensive, can be easily placed in the doctors pocket and allow a rapid examination of the skin [6]. Many newer devices use cross-polarized light to visualize cutaneous structures, and as such do not require direct physical contact between the optical lens and the skin. In this way, they can be employed without the risk of possible transection, although this risk is generally considered low even with traditional oil-immersion (contact) dermatoscopes [7–9]. The factors listed above may explain why dermoscopy, apart from its classical application for the diagnosis of skin tumors, has also recently become popular for the in-vivo diagnosis of infectious skin conditions [10].

Among a range of skin infections and infestations, specific dermoscopic patterns have been described for viral warts, molluscum contagiosum, scabies, pediculosis, tinea nigra, tungiasis, CLM and ticks. Besides the diagnostic role of dermoscopy, there is increasing

evidence that it can also assist in the monitoring of treatment efficacy for some of these infectious conditions.

In this article, we provide an overview of the dermoscopic features of skin infections or infestations based on the current literature and our personal experience.

Search Strategy and Selection Criteria

Data for this review were identified by searches of Medline, Medscape and published abstracts of the 1st World Congress of the International Dermoscopy Society held on April 27–29th, 2006 in Naples, Italy. All articles that have been published until the 1st March 2007 were included. Search terms (in alphabetic order) were 'cutaneous larva migrans', 'cutaneous infection', 'dermatoscopy', 'dermatoscopic', 'dermoscopy', 'dermoscopic', 'drug resistance', 'epiluminescence microscopy', 'head lice', 'human parasites', 'infection', 'infectious', 'ixodes ricinus', 'molluscum contagiosum', 'pediculosis', 'phthirus pubis', 'scabies', 'tick', 'tinea nigra', 'tungiasis', 'verruca', and 'viral wart'. Only English- and German-language papers were reviewed.

Viral Skin Infections

Viral Warts

Cutaneous warts are common benign epidermal proliferations caused by various strains of the human papilloma virus. According to their anatomic location, warts are commonly classified as verruca vulgaris (common warts, typically involving human papilloma virus strains 2 or 7), verruca plantaris or palmaris (plantar or palmar warts, strains 1, 2, 4), plane warts (strains 3, 10) and condyloma acuminata (anogenital warts, strains include 6, 11, 42, 43, 44). Although their diagnosis is usually based on typical clinical features, clinicians may sometimes be confronted with features that overlap with other skin lesions or that make an accurate diagnosis based on solely clinical grounds difficult.

Plane Warts

The dermoscopic hallmark of plane warts are regularly distributed, tiny, red dots on a light brown to yellow background (fig. 1a). The red dots correspond histopathologically to the apices of capillaries in the papillary dermis, and are referred to as dotted vessels in the literature [11–14]. In our experience, these features are helpful to

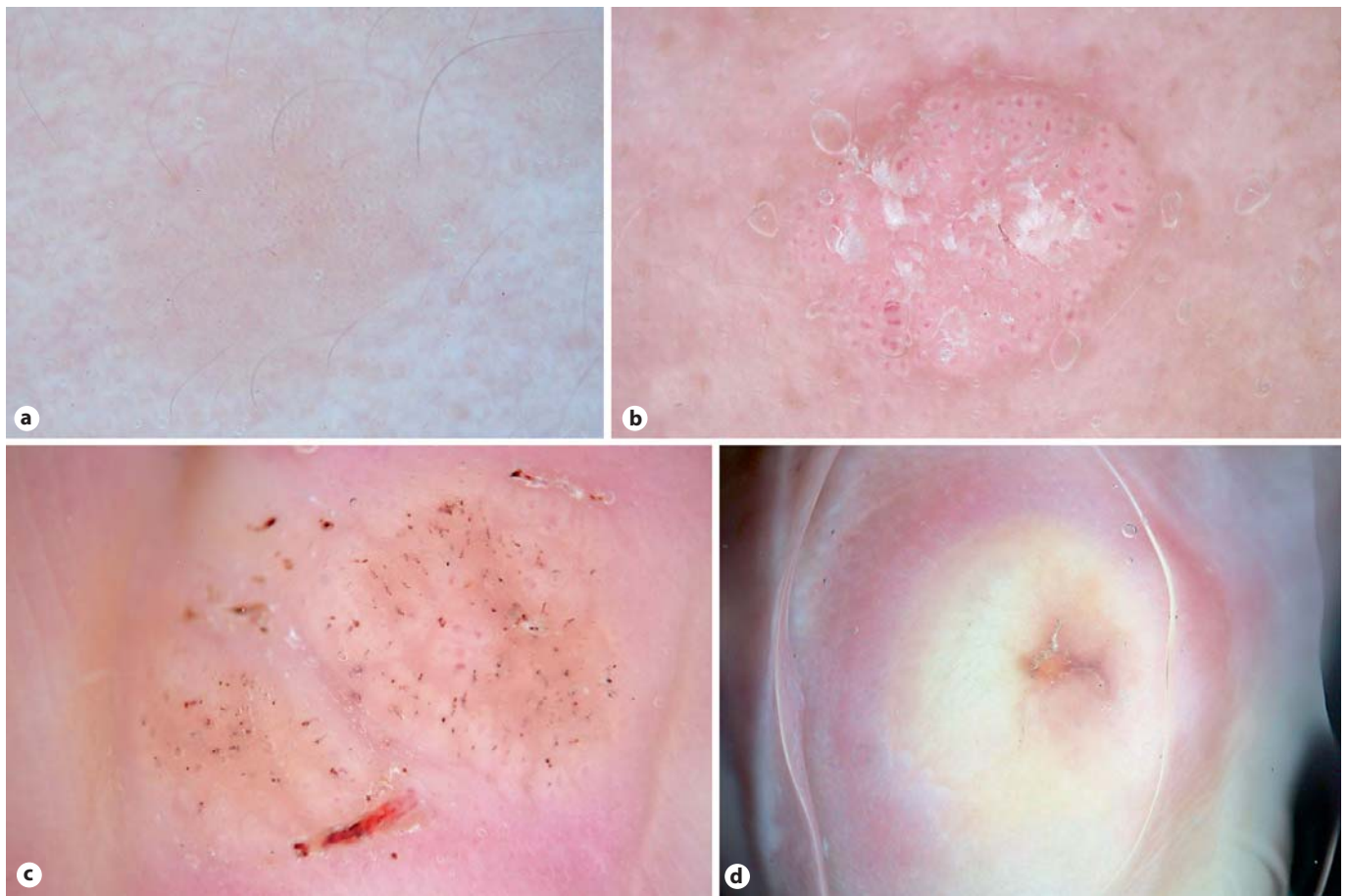

Fig. 1. **a** Dermoscopy of plane wart revealing tiny dotted (pin-point) vessels on a light brownish background. **b** Dermoscopy of verruca vulgaris. The dotted vessels are larger than in plane warts and located in the centre of the papillae (frogspawn). **c** Dermoscopy of verruca palmo-plantaris typically shows dots and brown

to red streaks that correspond to hemorrhages. **d** Dermoscopy of callus. Note the central bluish to reddish structureless area, which can help in selected cases to distinguish callus from warts. Original magnification $\times 10$.

distinguish plane warts from acne cysts or inflamed hair follicles, which by contrast, typically reveal a central white to yellow pore corresponding to the comedo or pus within the hair follicle opening.

Verruca Vulgaris

Dermoscopically, verruca vulgaris displays multiple densely packed papillae, each containing a central red dot or loop, which is surrounded by a whitish halo. This combination of features gives an appearance reminiscent of frogspawn. In contrast to plane warts, the dotted vessels are usually larger and often associated with hemorrhages. The latter appear as irregularly distributed, small, red to black to brown tiny dots or streaks (fig. 1b) [1–14]. These features are helpful to reassure an eventually clinical

doubtful diagnosis, for example in cases of irritated or subungual/periungual warts.

Verruca Plantaris

Plantar warts usually lack dotted or looped vessels. The dermoscopic diagnosis is based on the presence of a verrucous, yellowish structureless area exhibiting a variable number of irregularly distributed red to brown to black dots or linear streaks (hemorrhages), which are thought to be caused by the chronically high vascular pressure at plantar sites (fig. 1c). These hemorrhages are a helpful criterion to distinguish plantar warts from callus due to chronic friction, which lacks blood spots, but instead typically reveals central reddish to bluish structureless pigmentation (fig. 1d) [15–18]. Supplementary,

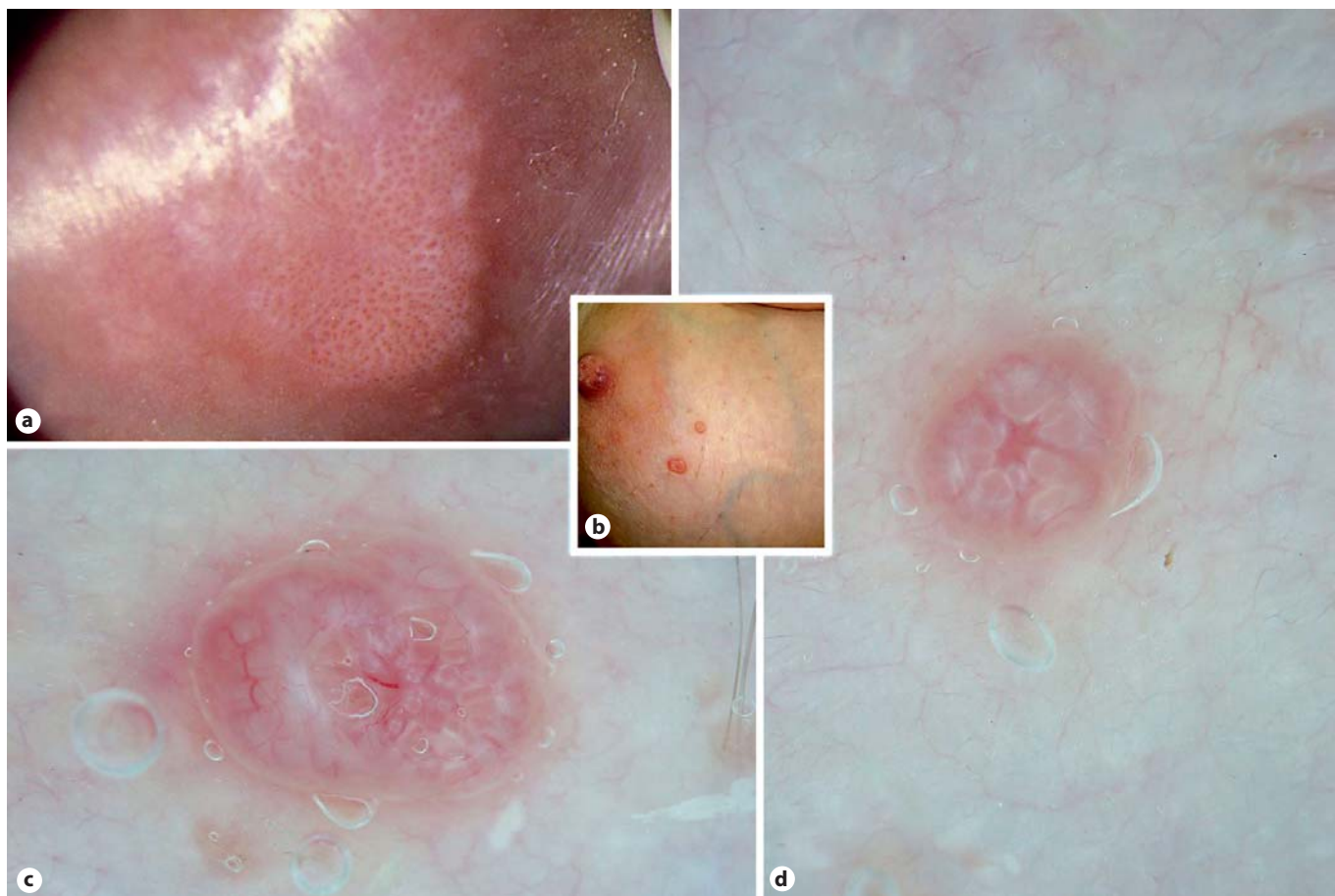


Fig. 2. **a** Dermoscopic view of genital wart revealing a white reticular network pattern. **b** Clinical image of molluscum contagiosum. **c, d** Dermoscopy of molluscum contagiosum as shown in **b** reveals a central polylobular amorphous structure surrounded by linear telangiectasias. Original magnification $\times 10$.

plantar warts should be always considered in the differential diagnosis of highly aggressive acral melanoma. In the latter, specific dermoscopic patterns such as pigmentation on the ridges (parallel ridge pattern) are highly specific and should always raise the index of suspicion. Despite the diagnostic impact, the presence of hemorrhages and vascular pattern may be also useful in monitoring the efficacy of the treatment of viral warts. That is, the disappearance of these patterns predict, in our personal experience, a cure or at least a low risk of recurrence.

Verruca Genitalis

To date, there is lack of literature describing the dermoscopic pattern of genital warts. However, in our experience genital warts exhibit a mosaic pattern consisting

of a white reticular network surrounding central small islands of unaffected mucosal skin (fig. 2a).

Molluscum Contagiosum

This skin infection is caused by a highly contagious human specific poxvirus. Dermoscopically, molluscum contagiosum displays a central pore or umbilication in association with polylobular white to yellowish amorphous structures, which are surrounded by linear, fine and blurred telangiectasias ('corona'-like vessels; fig. 2b-d) [19, 20]. These features are highly diagnostic allowing to differentiate molluscum contagiosum from many other skin lesions with high confidence. The rapid, noninvasive examination with the dermoscope appears useful especially in pediatric dermatology but also for patients with immunosuppression, in whom mollusca often appear clinically atypical.

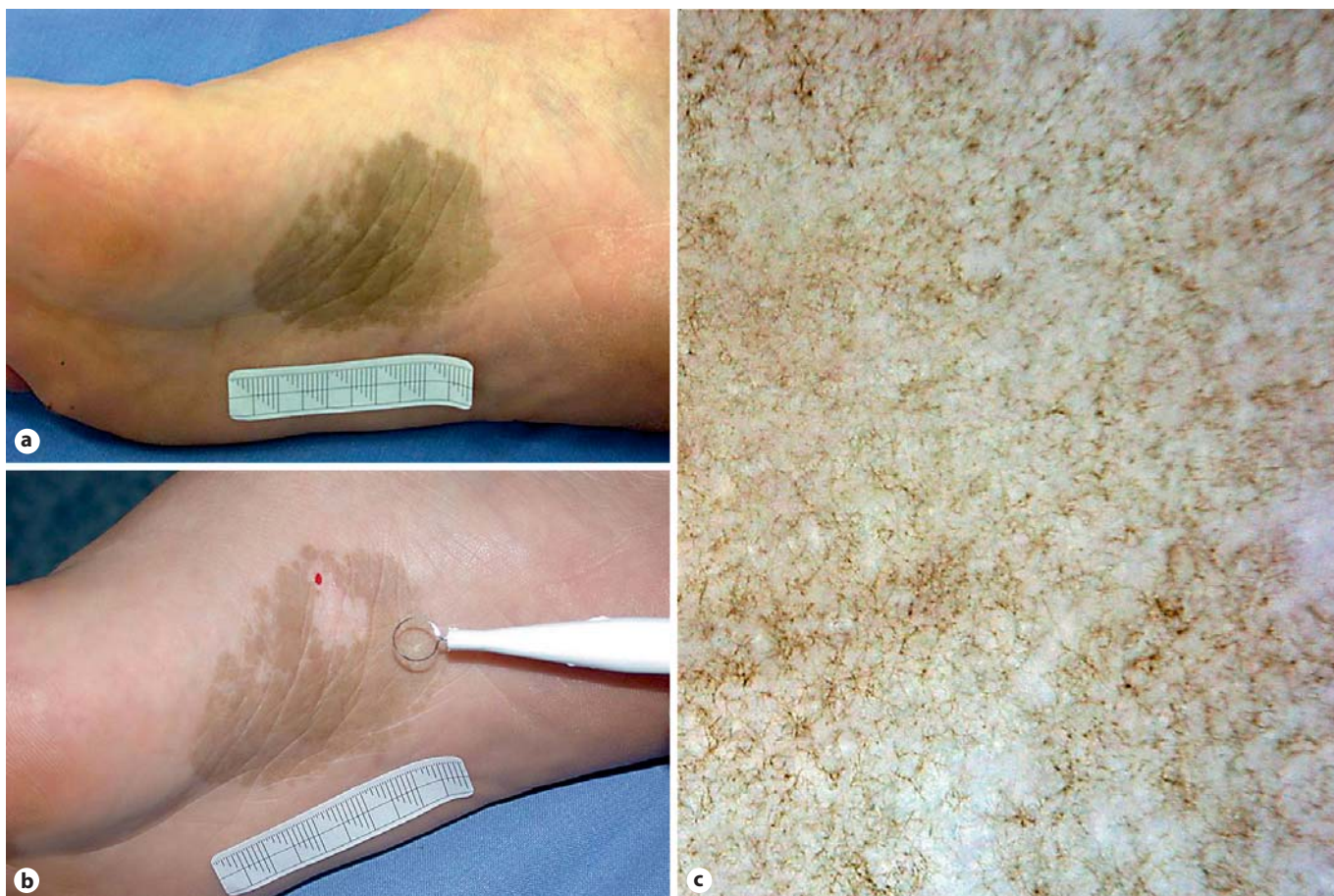


Fig. 3. **a** Clinical image of tinea nigra located on the sole. **b** Tinea nigra is a superficial mould infection that can be easily removed with a curette. **c** Dermoscopically, superficial fine, wispy, light brown strands or ‘pigmented spicules’ are seen, which do not follow the furrows and ridges of the glabrous skin. Original magnification $\times 10$.

Fungal Infections

Tinea Nigra

Tinea nigra is a superficial mould infection caused by *Phaeoannellomyces werneckii*, also known as *Exophiala werneckii*, *Exophiala phaeoannellomyces*, or *Cladosporium werneckii*. Infection commonly affects the glabrous skin of children or young adults living in or traveling to tropical or subtropical areas of South and Central America, Asia, and Africa. Clinically, tinea nigra palmaris or plantaris usually presents as a gradually enlarging, irregular brown to black macule, which can mimic melanocytic lesions, including acral melanoma (fig. 3a, b). However, in contrast to acral melanocytic lesions the dermoscopy of tinea nigra shows superficial fine, wispy, light brown strands or ‘pigmented spicules’, which form an al-

most reticulated-appearing patch (fig. 3c). Furthermore, the pigmentation does not conform to the furrows or ridges of the volar skin, as is typically the case for acral melanocytic skin lesions [21, Hawfield et al., unpubl. obs.].

Human Parasites

Scabies is caused by a skin infestation with the mite *Sarcoptes scabiei* var. *hominis*, which is a ubiquitous human ectoparasite. The leading clinical symptom is pruritus associated with cutaneous, often eczematous features. Because these clinical manifestations are highly unspecific, the clinical diagnosis should be confirmed by the traditional ex vivo identification of the mite, its eggs, or feces in skin scrapings under light microscopy.

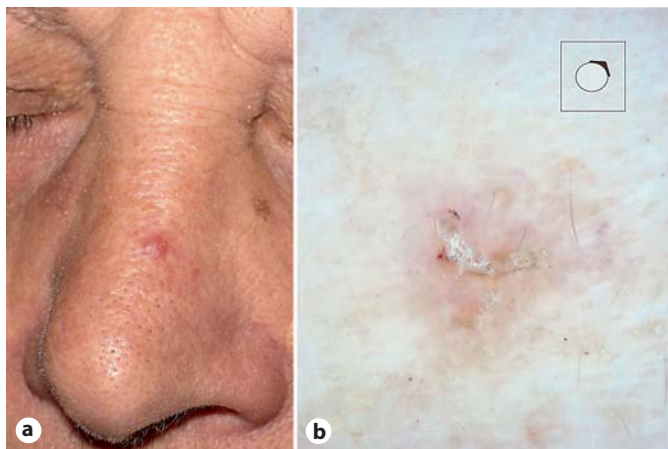


Fig. 4. **a** Unusual clinical presentation of scabies involving the face, occurring in a patient with poorly controlled diabetes mellitus. **b** While clinically the small red papule on the nose seems unspecific, dermoscopy allows the immediate identification of the mite at the end of the burrow. **Inset** Schematic drawing of the dermoscopic appearance of the mite. The anterior part is visible as a brown triangle, while the mites' posterior body is translucent. Original magnification $\times 10$.

Argenziano et al. [22] were the first reporting on the utility of dermoscopy in diagnosing scabies. In their study, they found in 93% of patients affected by *Sarcoptes scabiei* var. *hominis* repetitive dermoscopic findings of small dark brown triangular structures located at the end of whitish structureless, typically curved or wavy lines, giving an appearance reminiscent of a delta-wing jet with contrail (fig. 4). On microscopic examination, the brown triangle corresponds to the pigmented anterior part of the mite (i.e. the mouth parts and the two anterior pairs of legs), while the posterior part including the abdomen and hind legs appear translucent and are subsequently not seen by dermoscopy. By contrast, the burrow of the mite correlates dermoscopically to the contrail feature eventually revealing multiple small brown dots, with the latter corresponding to fecal pellets. Subsequent investigations confirmed these previous findings and demonstrated the utility of dermoscopy in the diagnosis of scabies [23–26]. In a further recent trial comparing the dermoscopic diagnosis of scabies with the traditional ex vivo microscopic examination, it has been shown that dermoscopy achieves not only comparable high diagnostic sensitivity values as the standard ex vivo diagnosis (91 vs. 90%, respectively), but also improved the diagnostic skills for making treatment decisions even among inexperienced clinicians [27]. Despite this, dermoscopy was also

significantly less time-consuming than the ex vivo microscopic examination. Our experience confirms these results and dermoscopy is already today an established diagnostic procedure for the diagnosis of scabies in most of our departments.

Treatment Monitoring

The disappearance or healing of all existing lesions, no formation of new lesions, and the inability to detect any dermoscopic 'jet with contrail' features on the entire cutaneous surface herald successful treatment. Of note, the clinical symptom of itch may persist for 4–6 weeks after successful eradication of the scabies mite [28, 29].

Tungiasis

Tungiasis is an endemic skin infestation caused by the sand flea *Tunga penetrans*. The female flea penetrates and imbeds into the epidermis, nourished from the blood of the dermal vascular plexus. This parasite is mainly distributed in the tropical regions of South and Central America, Africa, Asia and the Caribbean Islands, where its clinical manifestations are well recognized. By contrast, tungiasis outside endemic areas is rare and subsequently, its clinical features are less recognized and may cause delayed diagnosis of infestations with *tunga penetrans* with its related risk of secondary bacterial infections and inflammation. However, the facilities of worldwide travels suggest that individuals presenting with tungiasis outside the usual geographic area will be increasingly seen in clinical practice.

In these situations, dermoscopy guides to the correct diagnosis by revealing typically a white to light brown to flesh colored nodule with a central targetoid brownish ring surrounding a black central pore, which corresponds to the posterior part of the flea's exoskeleton. Sometimes, a grey blue blotch can be additionally seen which is thought to correlate with the abundance of eggs in the parasite's abdomen (fig. 5a, b) [30–32].

Cutaneous Larva Migrans

CLM, or creeping eruption, is caused by various animal hookworm (helminths) species such as *Ancilostoma braziliense*, *Ascaris suum*, *Bunostomum phlebotomum*, to name a few, which are acquired by direct contact with soil contaminated with dog or cat feces. The larva typically penetrates and burrows within the skin of the foot. In a report by Elsner et al. [33], the larva of CLM was detected by dermoscopy at $40\times$ magnification, but in another study of 18 patients, the diagnosis of CLM was established by history and clinical examination, and only one larva was visual-

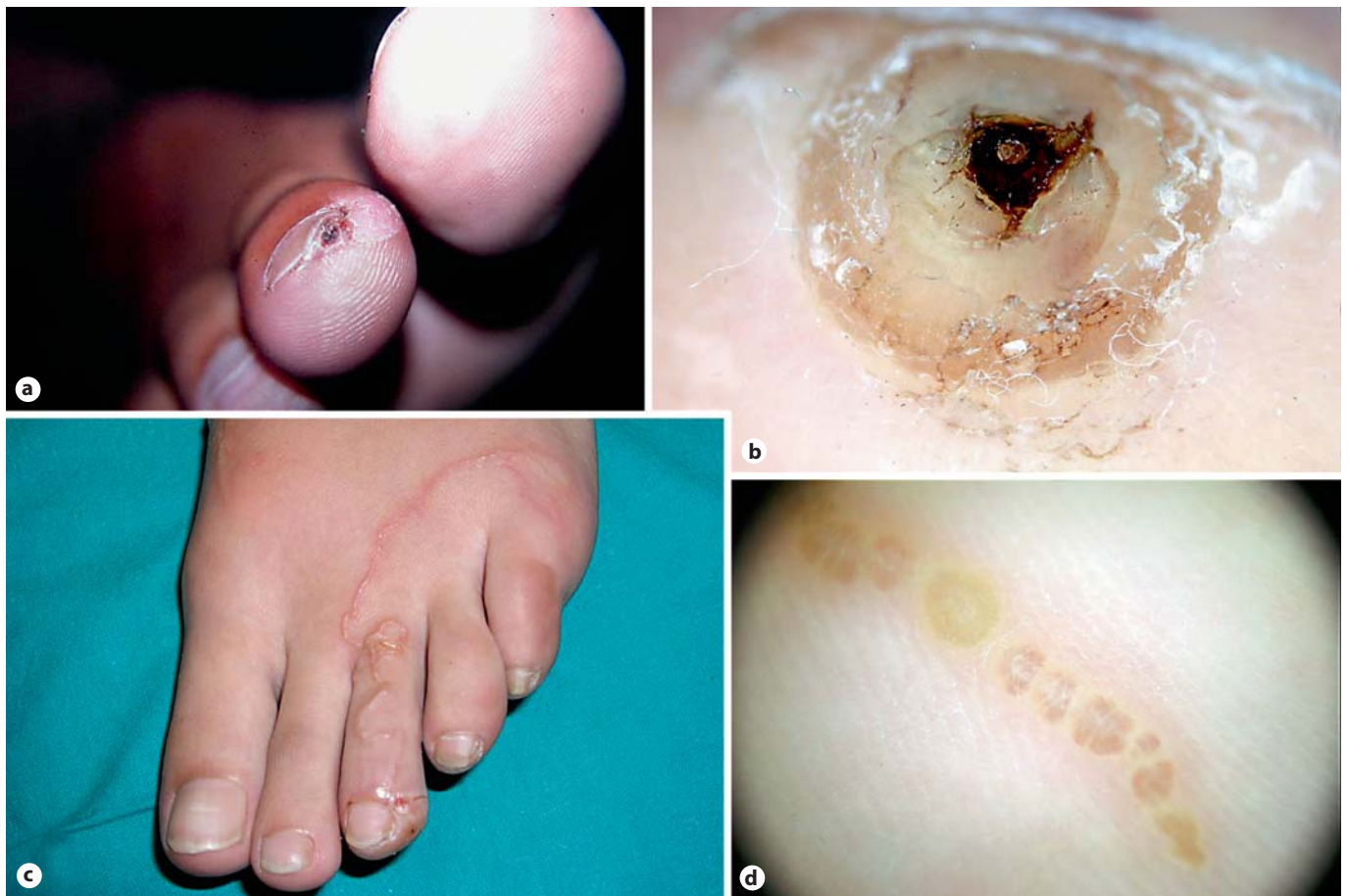


Fig. 5. Clinical (a) and dermoscopic features (b) of tungiasis. Dermoscopically, a whitish to light brown nodule with a central targetoid-appearing pore can be seen, which corresponds to the posterior part of the fleas' exoskeleton. Clinical (c) and dermoscopic image (d) of CLM. Dermoscopic view of the body of the parasite reveals brownish to yellow segments. Original magnification $\times 10$.

ized within one lesion in one patient by dermoscopy [34]. However, in this latter study dermoscopy was limited to a standard $10\times$ magnification, which could account for the low sensitivity in detecting larva. The efficacy of dermoscopy for the diagnosis of CLM has therefore not been adequately established, and further reports (using standard and high magnification) are needed.

In our own unpublished observations, we have found dermoscopy a useful adjunct for the diagnosis of the hookworm. In a recent case, the characteristic clinical features and symptoms of CLM were encountered, which suggested the diagnosis (fig. 5c, d). Nonetheless, dermoscopy revealed translucent brownish structureless areas in a segmental arrangement, which corresponded to the body of the larva, while the empty burrow revealed red-dotted vessels on dermoscopy.

Pediculosis Capitis and Pubis

Pediculus humanis capitis and *Phthirus pubis* are worldwide ectoparasites causing thousands of infestations per year. Dermoscopy allows a rapid and reliable diagnosis of these infestations by permitting the identification of the lice itself or the nits fixed to the hair shaft (fig. 6a, b). It has been recently reported that nits containing vital nymphs could be dermoscopically distinguished from empty nits and so-called pseudo-nits, such as hair casts, debris of hair spray or gel, or scales from seborrheic dermatitis. In vivo dermoscopy of nits containing nymphs reveals ovoid, brown structures while the empty nit cases are translucent and typically show a plane and fissured free ending. In contrast, pseudo-nits are not attached to the hair shaft and appear dermoscopically as amorphous, whitish structures. The dermoscopic differ-

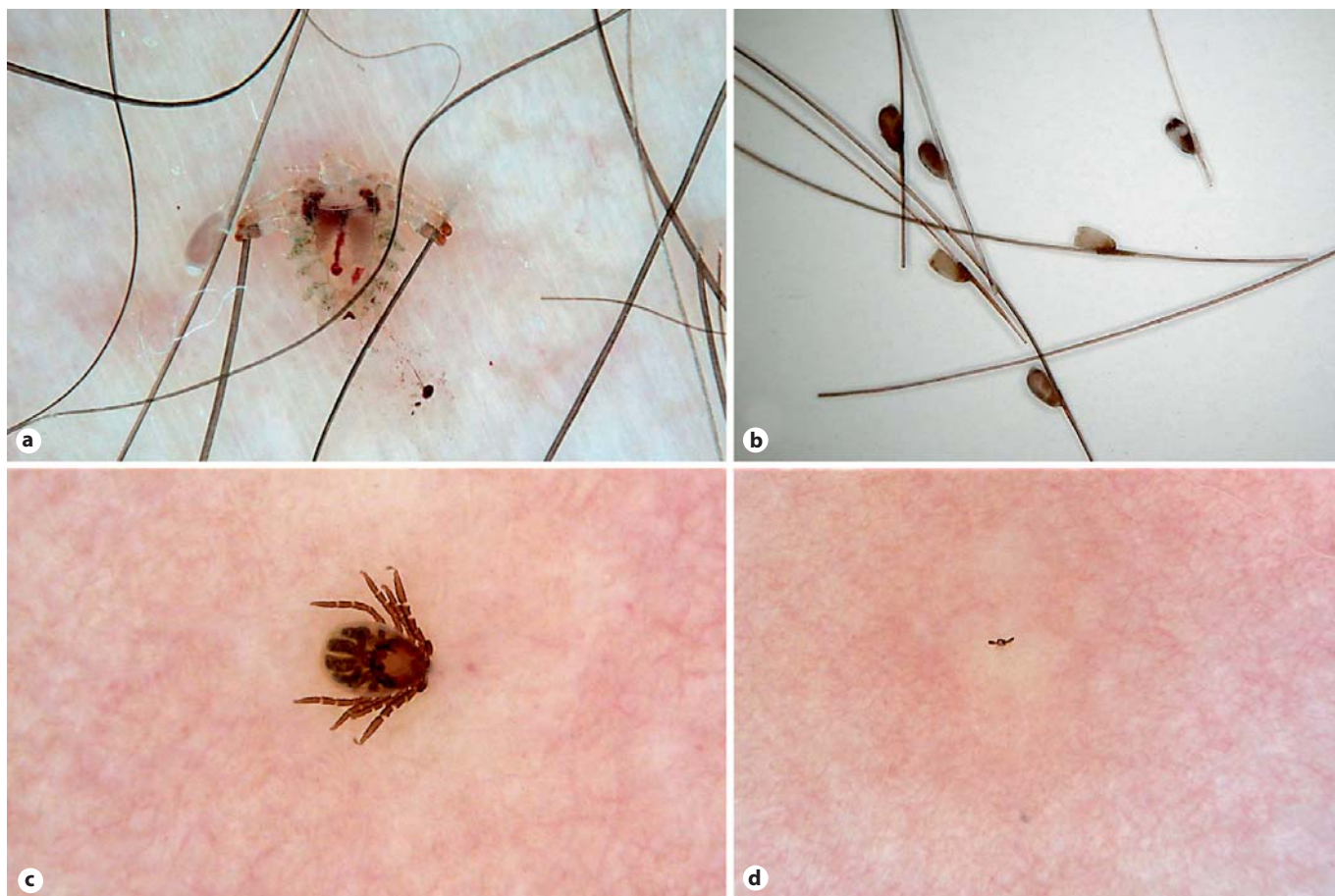


Fig. 6. **a** Dermoscopic view of *P. pubis*. **b** Dermoscopy of nits fixed to the hair shafts. Vital nits reveal an ovoid shape and a brown color, while empty nits have a flat end and are translucent. **c** Dermoscopy of the tick *I. ricinus* fixed in the skin. **d** Dermoscopy after incomplete removal of the tick. Remnants of the anterior part of the tick (head and pair of anterior legs) are recognizable in the skin. Original magnification $\times 10$.

ences between vital and empty nits also appear useful in monitoring treatment efficacy, in that the presence of vital nits should lead to a continuation or modification of therapy [35, 36]. The utility of dermoscopy in the diagnosis of pediculosis capitis has been recently confirmed by a larger series of patients by Scanni and Bonifazi [37], who also introduced the term 'entodermoscopy'.

Other Indications

Ixodes Ricinus

I. ricinus is a human parasite transmitting various infections, such as Lyme borreliosis or ehrlichiosis, to name just a few. Ticks are often small (less than 1 mm) and in clinically doubtful situations, dermoscopy provides a

convenient magnification and confirmation of the diagnosis. *I. ricinus* exhibits dermoscopically the double pair of anterior legs protruding from the surface of the skin, while the chitinous body is seen as a brown to grey translucent 'shield' with pigmented streaks (fig. 6c) [38]. Furthermore, dermoscopy is useful to detect whether the tick has been completely extracted from the skin, since incomplete removal reveals parts of the ticks head (including mouthparts), which appear dermoscopically as brown to black to grey areas of pigmentation (fig. 6d).

Spider Leg Spines

Recently, dermoscopy has been also found to aid the diagnosis of pruritic erythematous papules between the fingers caused by cutaneous reaction to spider spines of Brazilian black tarantula (*Grammostola pulchra*) clini-

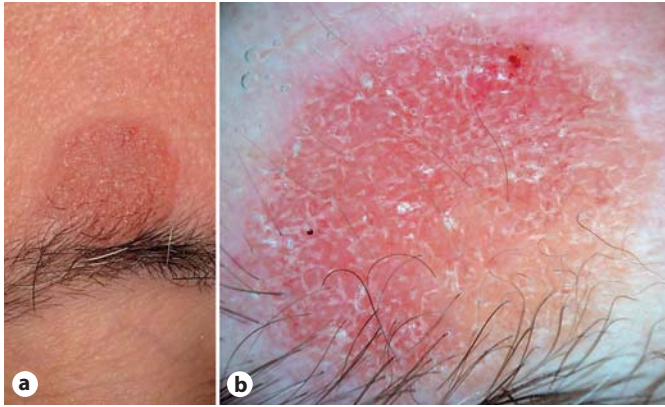


Fig. 7. **a** Clinical image of lupus vulgaris located on the face. **b** Dermoscopically, an orange to golden pigmentation along with focused linear telangiectasias are seen. In addition, whitish reticulated streaks and surface scaling can be appreciated. Original magnification $\times 10$.

cally mimicking scabies. In this case, dermoscopy revealed small black spines compatible with spider leg spines instead of the 'jet with contrail' features typically seen in scabies [39].

Lupus Vulgaris

Lupus vulgaris is rare, but the most common, chronic progressive and destructive form of cutaneous tuberculosis (*Mycobacterium tuberculosis*) in tuberculin-positive individuals. The clinical presentation is variable and ranges from mostly solitary, small nodules to large plaques with a predilection for the head and neck. Typical is the

gelatinous consistency of lesions, which is known as the apple jelly sign.

Although there is lack of literature on dermoscopic pattern seen in cutaneous tuberculosis, we have recently observed in 4 patients affected by lupus vulgaris, repetitive dermoscopic patterns of an orange to golden background pigmentation along with focused linear telangiectasias and an overlying whitish hue or whitish reticulated streaks (fig. 7). Certainly, this preliminary observation needs further confirmation on a larger series of cases.

Conclusion

Entodermoscopy has opened a new and interesting field connecting entomology, infectiology and dermatology, despite representing a fast and easily applicable non-invasive aid for the clinical diagnosis of many skin infections and infestations. In times of an increasing use and subsequent increasing accessibility of dermoscopy in the daily practice of many clinicians, this tool has the potential to expand its application from diagnosing skin tumors to skin lesions in general dermatology. We have aimed to provide the reader with a comprehensive overview on the current literature on this topic and with the most typical examples of the current applications of dermoscopy in the field of skin infections. Nevertheless, the most effective way for the clinicians to become familiar with the dermoscopic features remains the use of dermoscopy in everyday clinical practice.

References

- 1 Heukelbach J, Feldmeier H: Ectoparasites – the underestimated realm. *Lancet* 2004;363: 889–891.
- 2 Meinking TL: Clinical update on resistance and treatment of Pediculosis capitis. *Am J Manag Care* 2004;10:S264–S268.
- 3 Downs AM: Managing head lice in an era of increasing resistance to insecticides. *Am J Clin Dermatol* 2004;5:169–177.
- 4 Argenziano G, Soyer HP, Chimenti S, et al: Dermoscopy of pigmented skin lesions: results of a consensus meeting via the Internet. *J Am Acad Dermatol* 2003;48:679–693.
- 5 Braun RP, Rabinovitz HS, Oliviero M, Kopf AW, Saurat JH: Dermoscopy of pigmented skin lesions. *J Am Acad Dermatol* 2005;52: 109–121.
- 6 Arrazola P, Mullani NA, Abramovits W: DermLite II: an innovative portable instrument for dermoscopy without the need of immersion fluids. *Skinmed* 2005;4:78–83.
- 7 Kelly SC, Purcell SM: Prevention of nosocomial infection during dermoscopy? *Dermatol Surg* 2006;32:552–555.
- 8 Hausermann P, Widmer A, Itin P: Dermatoscope as vector for transmissible diseases – no apparent risk of nosocomial infections in outpatients. *Dermatology* 2006;212:27–30.
- 9 Stauffer F, Kittler H, Forstinger C, Binder M: The dermatoscope: a potential source of nosocomial infection? *Melanoma Res* 2001;11: 153–156.
- 10 Zalaudek I, Argenziano G, Di Stefani A, Ferrara G, et al: Dermoscopy in general dermatology. *Dermatology* 2006;212:7–18.
- 11 Teoli M, Di Stefani A, Botti E, Mio G, Chimenti S: Dermoscopy for treatment monitoring of viral warts. *Dermatology* 2006;212: 318.
- 12 Steiner A, Pehamberger H, Wolff K: In vivo epiluminescence microscopy of pigmented skin lesions. II. Diagnosis of small pigmented skin lesions and early detection of malignant melanoma. *J Am Acad Dermatol* 1987; 17:584–591.
- 13 Pehamberger H, Steiner A, Wolff K: In vivo epiluminescence microscopy of pigmented skin lesions. I. Pattern analysis of pigmented skin lesions. *J Am Acad Dermatol* 1987;17: 571–583.

- 14 Vazquez-Lopez F, Kreusch J, Marghoob AA: Dermoscopic semiology: further insights into vascular features by screening a large spectrum of nontumoral skin lesions. *Br J Dermatol* 2004;150:226–231.
- 15 Akasu R, Sugiyama H, Araki M, Ohtake N, Furue M, Tamaki K: Dermoscopic and videomicroscopic features of melanocytic plantar nevi. *Am J Dermatopathol* 1996;18:10–18.
- 16 Altamura D, Altobelli E, Micantonio T, Piccolo D, Fargnoli MC, Peris K: Dermoscopic patterns of acral melanocytic nevi and melanomas in a white population in central Italy. *Arch Dermatol* 2006;142:1123–1128.
- 17 Dalmau J, Abellaneda C, Puig S, Zaballos P, Malvehy J: Acral melanoma simulating warts: dermoscopic clues to prevent missing a melanoma. *Dermatol Surg* 2006;32:1072–1078.
- 18 Kim HO, Bae JM, Kim YY, Lee WS, Cho JH, Kim MY, Park YM: Differential diagnosis of wart from callus and healed wart with aid of dermoscopy. *Dermatology* 2006;212:307.
- 19 Zaballos P, Ara M, Puig S, Malvehy J: Dermoscopy of molluscum contagiosum: a useful tool for clinical diagnosis in adulthood. *J Eur Acad Dermatol Venereol* 2006;20:482–483.
- 20 Morales A, Puig S, Malvehy J, Zaballos P: Dermoscopy of molluscum contagiosum. *Arch Dermatol* 2005;141:1644.
- 21 Smith SB, Beals SL, Elston DM, Meffert JJ: Dermoscopy in the diagnosis of tinea nigra plantaris. *Cutis* 2001;68:377–380.
- 22 Argenziano G, Fabbrocini G, Delfino M: Epiluminescence microscopy. A new approach to in vivo detection of *Sarcoptes scabiei*. *Arch Dermatol* 1997;133:751–753.
- 23 Prins C, Stucki L, French L, Saurat JH, Braun RP: Dermoscopy for the in vivo detection of sarcoptes scabiei. *Dermatology* 2004;208:241–243.
- 24 Bauer J, Blum A, Sonnichsen K, Metzler G, Rassner G, Garbe C: Nodular scabies detected by computed dermatoscopy. *Dermatology* 2001;203:190–191.
- 25 Weinstock MA, Kempton SA: Case report: teledermatology and epiluminescence microscopy for the diagnosis of scabies. *Cutis* 2000;66:61–62.
- 26 Brunetti B, Vitiello A, Delfino S, Sammarco E: Findings in vivo of *Sarcoptes scabiei* with incident light microscopy. *Eur J Dermatol* 1998;8:266–267.
- 27 Dupuy A, Dehen L, Bourrat E, Lacroix C, et al: Accuracy of standard dermoscopy for diagnosing scabies. *J Am Acad Dermatol* 2007;56:53–62.
- 28 Chouela E, Abeldano A, Pellerano G, Hernandez MI: Diagnosis and treatment of scabies: a practical guide. *Am J Clin Dermatol* 2002;3:9–18.
- 29 Hamm H, Beiteke U, Hoger PH, Seitz CS, Thaci D, Sunderkotter C: Treatment of scabies with 5% permethrin cream: results of a German multicenter study. *J Dtsch Dermatol Ges* 2006;4:407–413.
- 30 Di Stefani A, Rudolph CM, Hofmann-Wellenhof R, Mullegger RR: An additional dermoscopic feature of tungiasis. *Arch Dermatol* 2005;141:1045–1046.
- 31 Bauer J, Forschner A, Garbe C, Rocken M: Variability of dermoscopic features of tungiasis. *Arch Dermatol* 2005;141:643–644.
- 32 Bauer J, Forschner A, Garbe C, Rocken M: Dermoscopy of tungiasis. *Arch Dermatol* 2004;140:761–763.
- 33 Elsner E, Thewes M, Worret WI: Cutaneous larva migrans detected by epiluminescence microscopy. *Acta Derm Venereol* 1997;77:487–488.
- 34 Veraldi S, Schianchi R, Carrera C: Epiluminescence microscopy in cutaneous larva migrans. *Acta Derm Venereol* 2000;80:233.
- 35 Di Stefani A, Hofmann-Wellenhof R, Zalaudek I: Dermoscopy for diagnosis and treatment monitoring of pediculosis capitis. *J Am Acad Dermatol* 2006;54:909–911.
- 36 Di Stefani A, Hofmann-Wellenhof R, Zalaudek I, Papoutsaki M, Teoli M, Chimenti S: Usefulness of dermoscopy in louse infestations. *Dermatology* 2006;212:302.
- 37 Scanni G, Bonifazi E: Viability of the head louse eggs in pediculosis capitis. A dermoscopy study. *Eur J Pediatr Dermatol* 2006;16:201–204.
- 38 Pagliarello C, Fossati B, Landi F, Proietti I, Paradisi A, Capizzi R, Amerio P: Dermoscopy of a tick bite: a case report. *Dermatology* 2006;212:313.
- 39 Bakos RM, Rezende RL, Bakos L, Cartell A: Spider spines detected by dermoscopy. *Arch Dermatol* 2006;142:1517–1518.